Nuclear medicine in diagnosis and therapy of neuroendocrine tumours

Jean-Mathieu Beauregard, MD, MSc, FRCPC
Assistant Professor, Radiology, Université Laval
Nuclear Medicine Physician, Medical Imaging, CHU de Québec

Ottawa Patient Education Session
May 10th, 2014

Learning objective

To get an overview of the diagnostic and therapeutic procedures nuclear medicine has to offer to patients with NET

Nuclear Medicine

- The medical use of radioactive compounds called *radiopharmaceuticals* or tracers for diagnosis or therapy
- Diagnostic procedures consist in imaging the distribution of the tracer in the body
- Therapeutic procedures consist in delivering targeted *internal* radiotherapy using tracers that can also be imaged

"What you see is what you treat"

"If you don't see it, you can't treat it"

Radiology *vs.* Nuclear Medicine

Radiology = *anatomical* imaging

= looking under the hood

Radiology *vs.* Nuclear Medicine

Nuclear medicine = *functional* imaging

= looking at how things work

Diagnostic *vs.* Therapeutic Tracers

- Similarities
  - Both use a specific mechanism to target disease
  - Both can be imaged (scan or scintigraphy)
- Differences
  - Radiation type:
    - <u>rays</u> for diagnosis and imaging
    - <u>particles</u> for therapy
  - Doses:
    - very low for diagnosis
    - much higher for therapy

Diagnostic NM scans for NET

- Scintigraphy
  1. Octreoscan
  2. MIBG scan
  3. Bone scan
- PET scan
  4. FDG PET scan
  5. Gallium-68 PET scan

Scintigraphy

Gamma camera

Sometimes bundled with a CT scan

1. Octreoscan

- Octreoscan is an analogues of <u>somatostatin</u>
  - ^{111}In-octreotide
  - like a radioactive "Sandostatin®"
- <u>Somatostatin</u> is a natural hormone:
  - regulates growth and digestive tract function
- <u>Receptors for somatostatin</u> are found:
  - Naturally in various organs
  - In higher number on many NET

1. Octreoscan

- Octreoscan is used to:
  a. Detect NET lesions
  b. Characterize lesions:
     - Is there somatostatin receptors? Is it a NET?
- About the procedure:
  - Patient needs to tell if on Sandostatin LAR or Somatulin
  - Injection of Octreoscan
  - Imaging 4 hr. (same day) and 24 hr. (next day)
    - Sometimes at 48 hr.

1. Octreoscan

Whole-body scan:

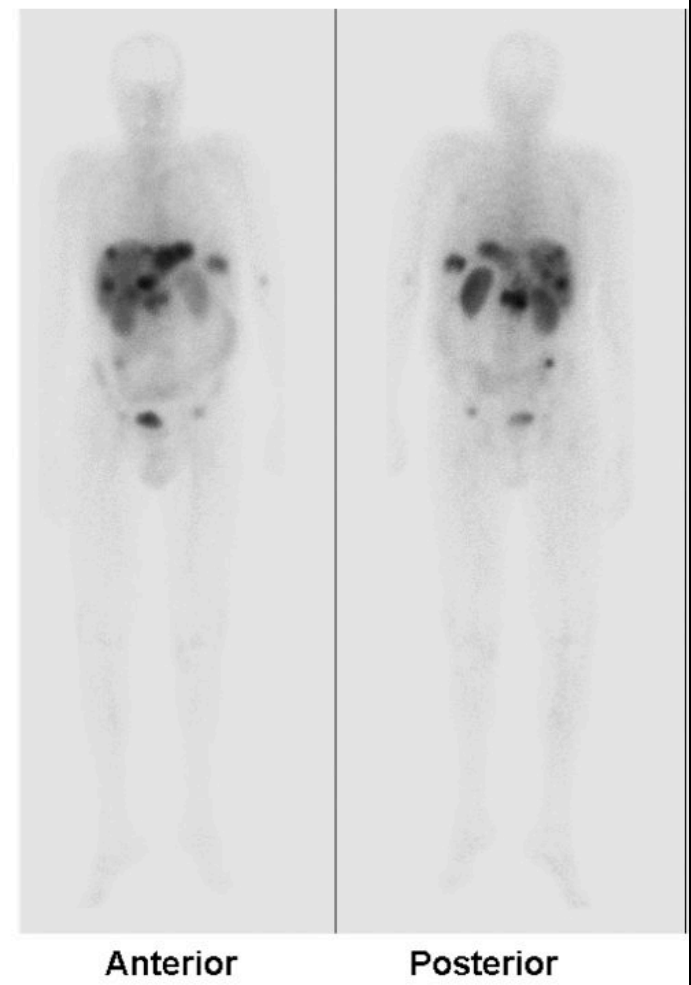

Hicks, Cancer Imaging 2010;10:S83-S91

1. Octreoscan

- 3D "SPECT" scan:

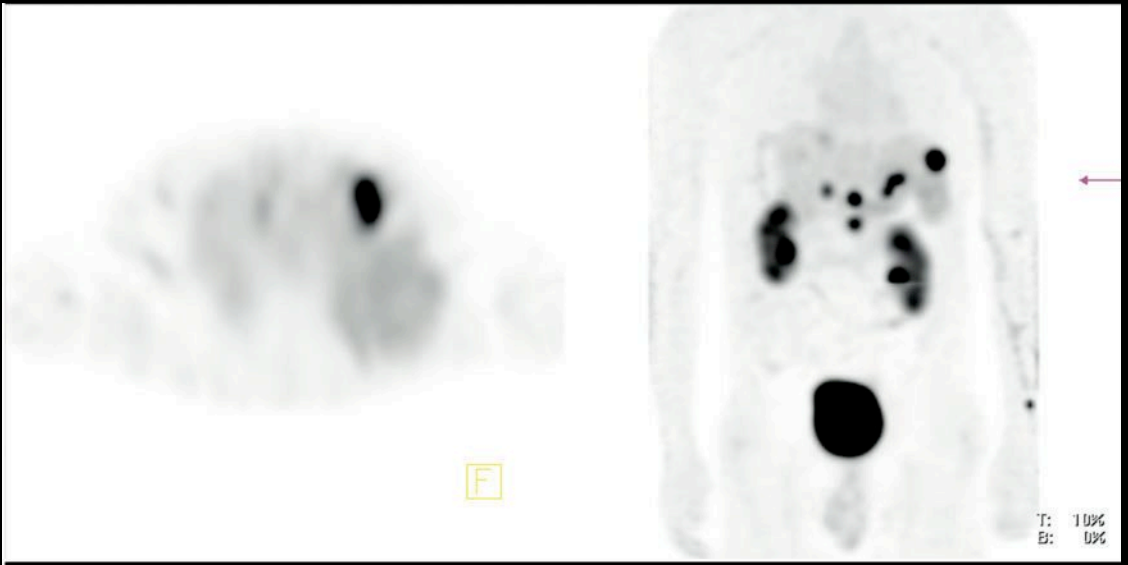

- Sometimes with CT:
  - Hybrid "SPECT/CT"

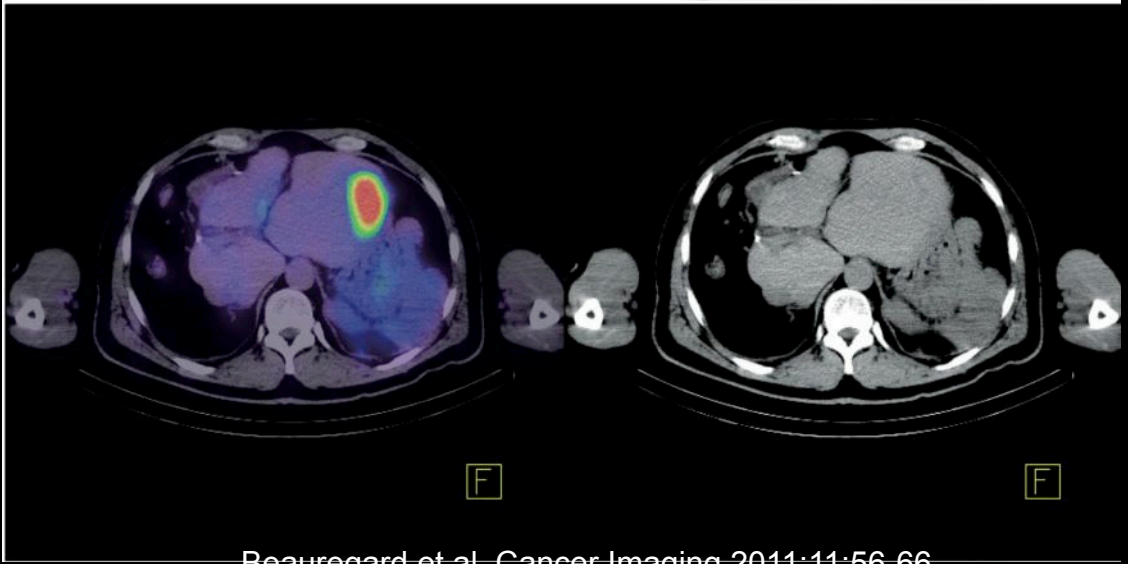

Beauregard et al. Cancer Imaging 2011;11:56-66

2. MIBG scan

- “Metaiodobenzylguanidine” labeled with iodine-123 or iodine-131
- Taken up by NET which produced hormones in the “amine” family:
  - Adrenalin (Pheochromocytoma)
  - Serotonin (Carcinoid)
- To detect and characterize NET lesions

2. MIBG scan

- Preparation:
  - Patient asked about his/her medication
    - Sometimes necessary to suspend some drug(s)
  - Take Lugol solution 2 days prior and 2 days (or more, as instructed) after scan
- Injection of MIBG
- Imaging protocols vary
  - Sometimes at 4 hr. (same day)
  - Standard at 24 hr. (next day)
    - or later if I-131-MIBG is used
  - Whole-body ± SPECT or SPECT/CT

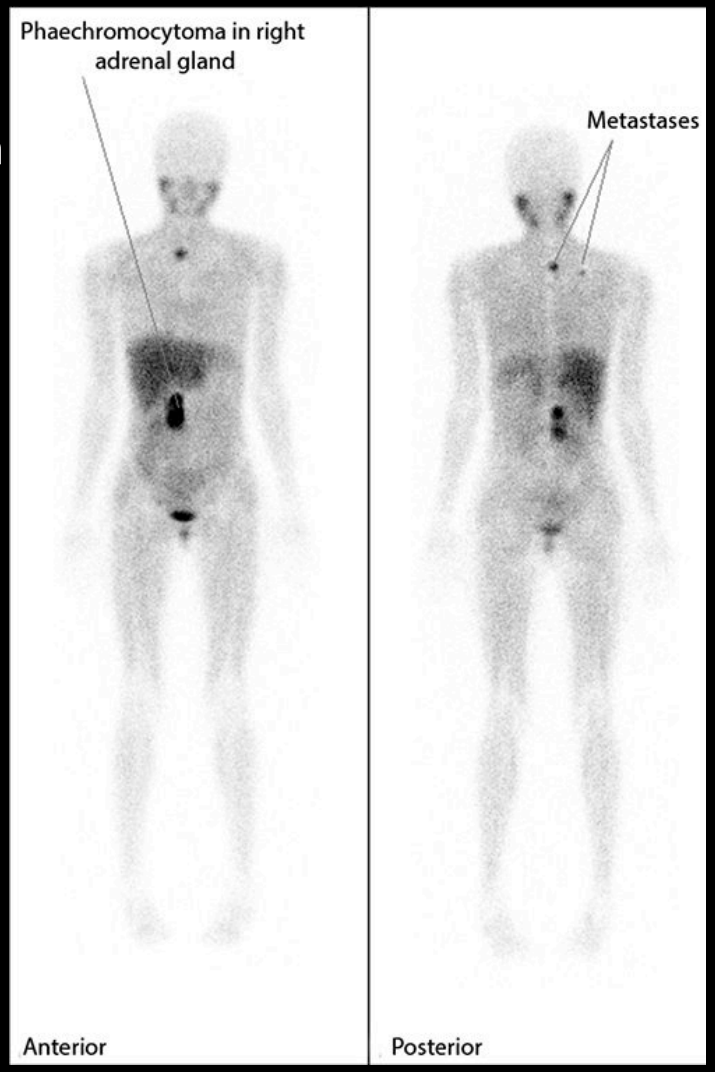

Kotze, T. Continuing Medical Education, 2013;31(8):284-288

3. Bone scan

- Using a tracer that binds to bones (labeled with Tc-99m)
- Detects tumours in the bones
- Takes about 4 hours
- Occasionally used for patients with NET
  - NET spread to bone less frequently than other cancers

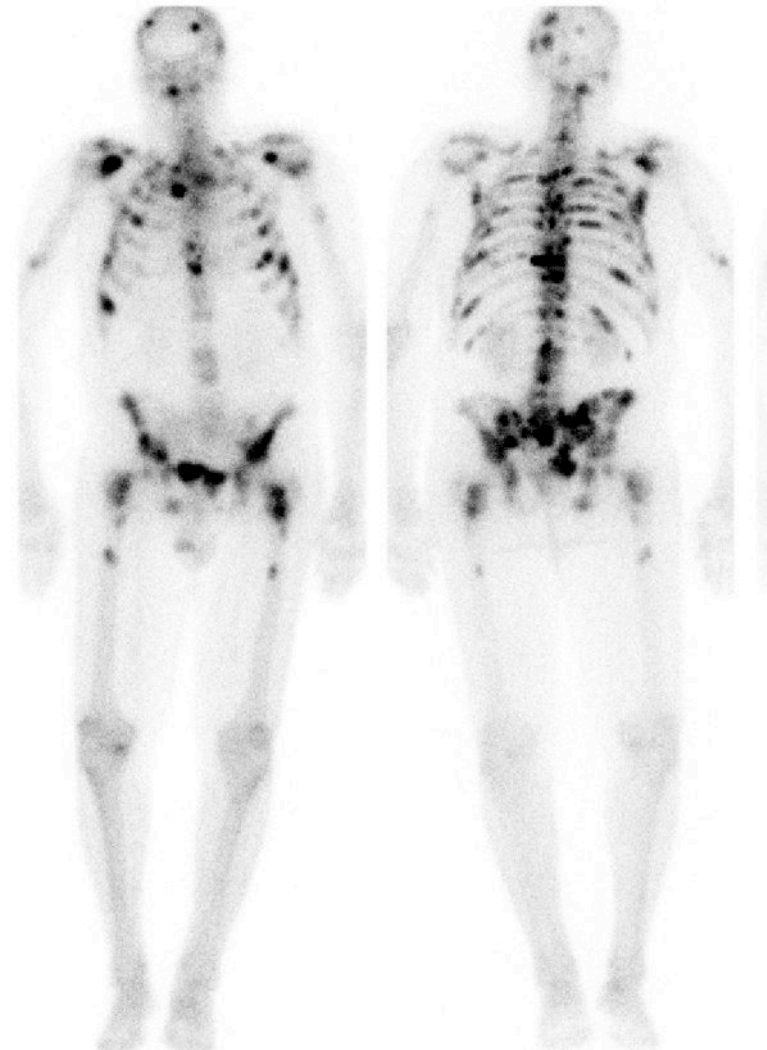

http://nucmedreview.com/cases/muskuloskeletal/muskuloskeletal.htm

PET scan

Positron Emission Tomography

Nowadays, always hybrid PET/CT scan

4. FDG PET scan

- ^{18}F-Fluorodeoxyglucose looks at how much glucose (sugar) tumours are burning
- Useful only for selected patients with NET
  - E.g.: Tumour is seen on CT or MRI but Octreoscan is negative
  - To assess the behaviour/agressiveness of tumours
  - To assess response to certain therapies
- Fasting needed
- ~2-hour procedure

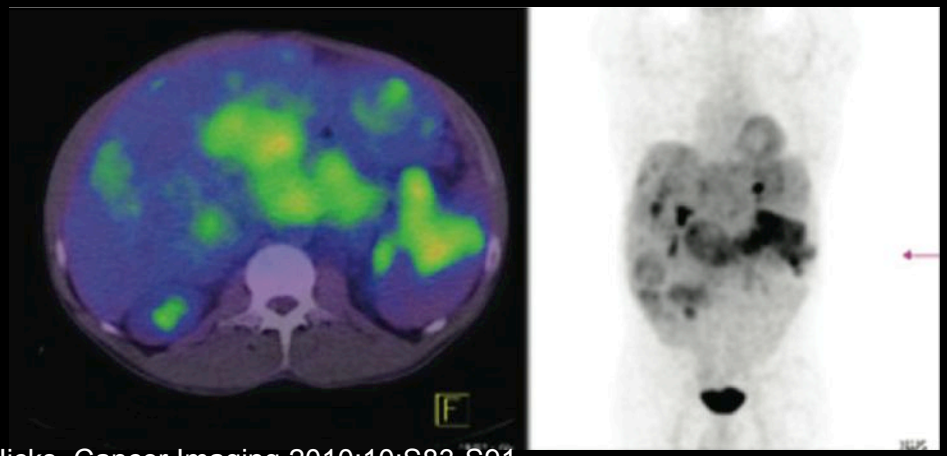

Hicks, Cancer Imaging 2010;10:S83-S91

5. Gallium-68 PET scan

- Uses various somatostatin analogues labelled with ^{68}Ga:
  - Octreotide, Octreotate, “DOTATOC”, “DOTATATE”, etc.
- Same as Octreoscan, but:
  - Faster (~2-hour total)
  - Higher resolution and sensitivity
- Limited availability in Canada due to:
  - Stringent regulations
  - Lack of industry baking
- However, for most cases, Octreoscan provides adequate diagnostic information

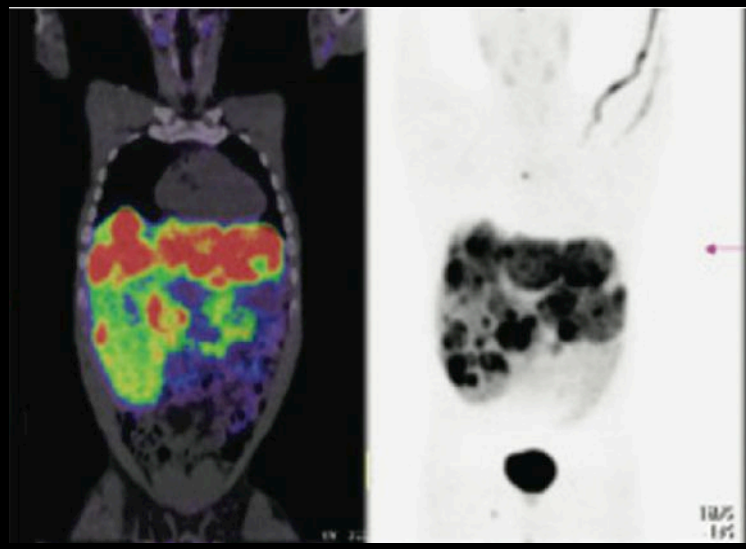

Hicks, Cancer Imaging 2010;10:S83-S91

Radionuclide therapies for NET

- Goal is to deliver radiation targeting as much as possible the NET lesions and sparing healthy organs
  - Radiation will cause greater damage and kill the tumour and cause little harm to the organs
  - Maximum therapeutic benefit may take many weeks to months after therapy to manifest
- For patient with metastatic/unresectable NET
  - Progressive disease despite medical treatment
  - Symptoms uncontrollable by medication
  - *Palliative*

Radionuclide therapies for NET

- Systemic
  - The tracer is injected intravenously, circulates in the body, and accumulates preferentially in the tumour lesions (wherever they are in the body)
    - PRRT
    - MIBG
- Regional
  - The tracer is injected in the liver artery and accumulates preferentially in the tumour lesions in that organ
    - Yttrium-90 microspheres

PRRT

- Peptide Receptor Radionuclide Therapy
- Tracers are analogues of somatostatin
- Eligibility based on tumour visualization on Octreoscan or Ga-68 PET scan
  - i.e. presence of somatostatin receptor on NET

Tracers for PRRT

- ^{111}In-octreotide (Octreoscan high dose)
  - Short-range particle radiations
  - Limited efficacy, rarely used nowadays
- ^{90}Y-octreotide (DOTATOC)
  - Long-range particle radiations
  - Used in selected cases
- ^{177}Lu-octreotate (DOTATATE)
  - Medium-range particle radiations
  - <u>Now the most popular PRRT agent</u>

^{177}Lu-octreotate PRRT

- 4 initial cycles, every 6-12 weeks
- Day-care procedure
  - Pre-medication (anti-nausea)
  - Amino acid infusion over 4 h (kidney protection)
  - Intravenous ^{177}Lu-octreotate administration
- One or more scans following each cycle
  - Often only at 24 or 48 hr.
  - Up to 3-4 days in some protocols

^{177}Lu-octreotate PRRT

- Well-tolerated by most patients
  - Acute side effects may include nausea, pain, increase in hormonal symptoms…
- Need to monitor blood counts during following weeks
- Main long-term side effect is a mild decrease in renal function
  - Seldom severe enough to require dialysis

^{177}Lu-octreotate PRRT

- ~2/3 patients will benefit from PRRT in terms of tumour size:
  - 1/3 tumour shrinkage
  - 1/3 tumour stabilization
- ~2/3 patients with pain or hormonal symptoms will have:
  - A reduction in symptoms intensity/frequency
  - Medications tapered or withdrawn
- Palliative treatment
  - Improves quality of life
  - Seems to prolong survival
- If there is any benefit, “maintenance”cycles may be administered periodically (e.g. 6-24 mo.)

Octreoscan before/after ^{177}Lu-octreotate

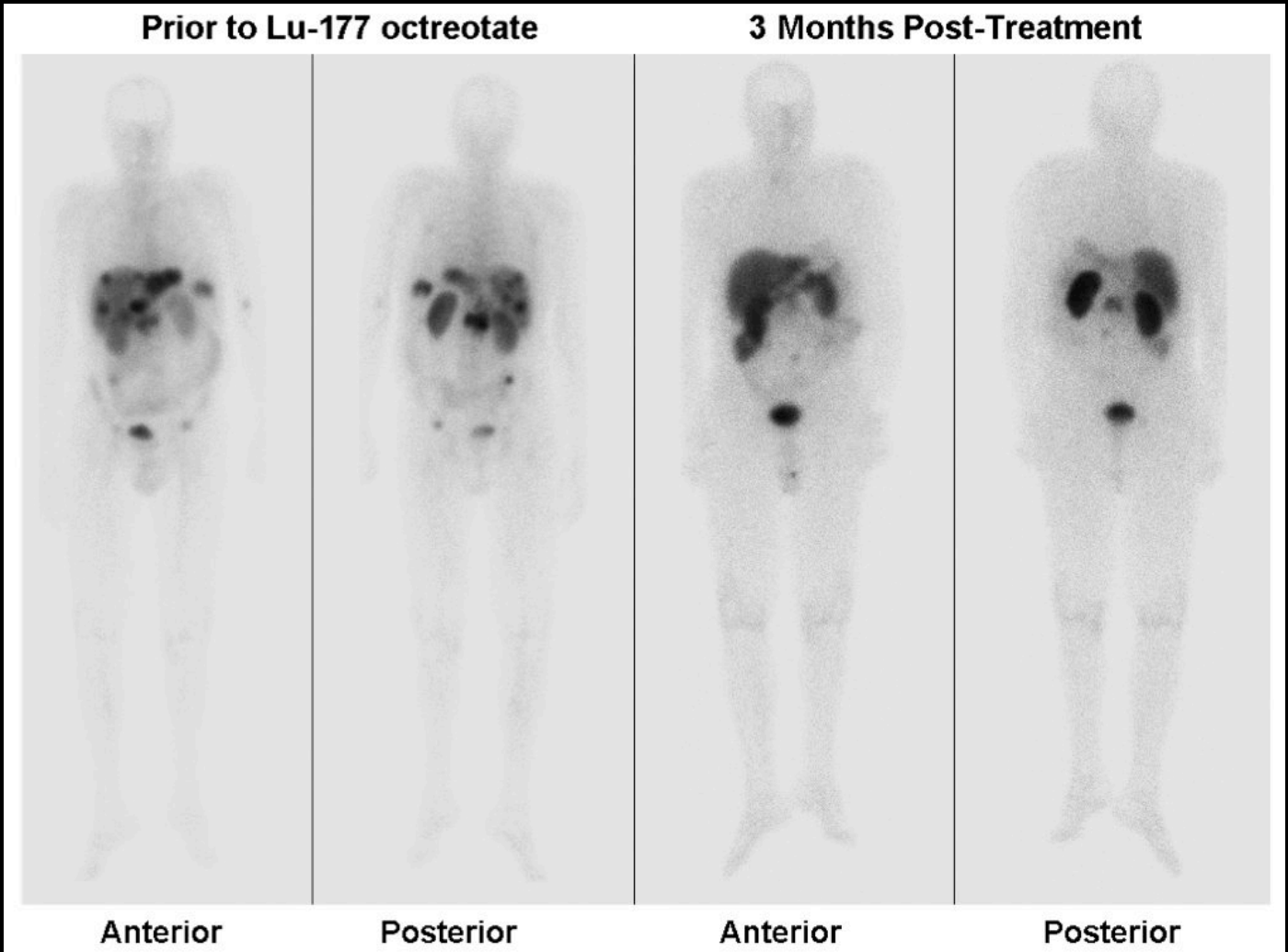

Hicks, Cancer Imaging 2010;10:S83-S91

PRRT in Canada

- Currently available under clinical trials at:
  - London Health Sciences Center
  - Edmonton Cross Cancer Institute
- Currently available under Special Access Program at:
  - CHU de Québec (Quebec City)
    - Soon under a clinical trial
- Available soon under a common trial at:
  - Princess Margaret Hospital
  - Sunnybrook Health Sciences Center
  - Hamilton Health Sciences

^{131}I-MIBG therapy

- Same tracer as MIBG scan, but at higher doses
- Radionuclide is iodine-131
  - Medium-range particle radiation
- Eligibility: MIBG scan must be positive

^{131}I-MIBG therapy

- Iodine (Lugol) solution pre-med to protect the thyroid gland
- Hospitalization required
  - higher rate of external radiations (rays that go outside the body)
- Blood-pressure monitoring during MIBG administration
- Scan about a week following therapy
- Can be administered as multiple cycles

^{131}I-MIBG therapy

- Most useful in pheochromocytoma and related NET
- Alternative radionuclide therapy for selected carcinoid patients
  - e.g. if Octreoscan is negative, but MIBG scan is positive
- Less radiation to kidney than PRRT, but more to the bone marrow
  - Causing more haematological toxicity (drop in blood counts)

^{131}I-MIBG

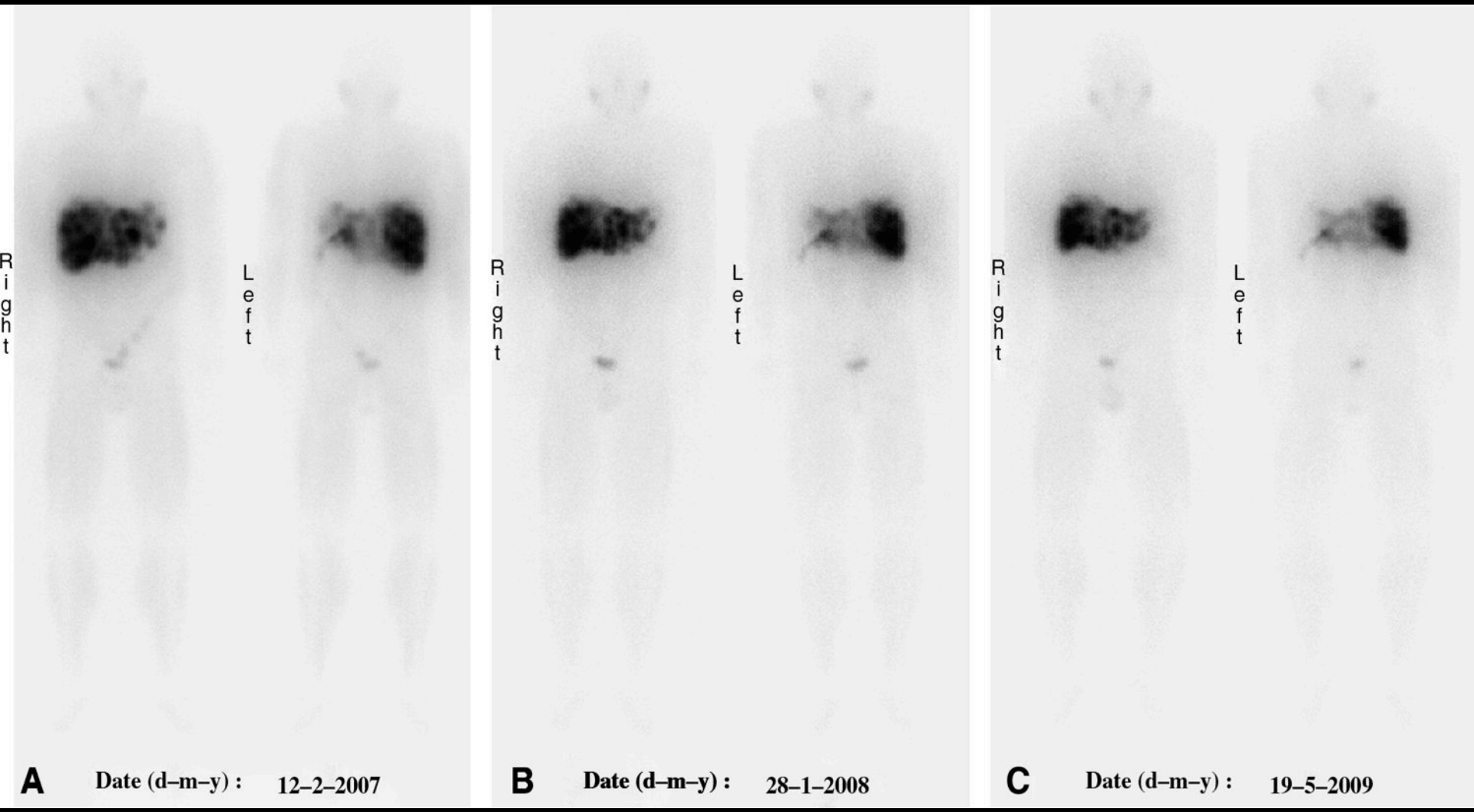

Postema EJ. Cancer Biother Radiopharm **24**:5, 519-25

^{90}Y-microspheres

- Radio-embolization
- Small beads of glass or resin to which yttrium-90 is bound
- Suitable for patients with metastasis in the liver only/mostly
- Needs the placement of a tube (catheter) in the liver artery by a radiologist
- The radioactive beads are injected into the liver artery
  - Trapped in the smallest blood vessels
  - The liver artery provides 25% of the blood flow to normal liver, but ~100% to the liver metastases
- Imaging same day or next

^{90}Y-microspheres

- Some contraindications:
  - Poor hepatic function
  - Blood “shunt”
- Side effects:
  - Can worsen liver function
    - Severe liver toxicity is rare
  - Complications in less than 5% (mostly gastro-intestinal)
- Promising results
  - Efficacy in the same range as PRRT

Nuclear medicine for NET

- Diagnostic scans
  - *Functional* imaging
  - Assess non-invasively specific features of NET
  - Complementary to radiology
- Radionuclide therapy
  - Uses specific features of NET to target tumours
  - Unique *"What you see is what you treat"* approach
  - Complementary to other medical/surgical therapies
  - Well-tolerated and promising results
- The nuclear medicine physician is now a key player in the Multidisciplinary Team, for the optimal care of patients suffering from NET


Thank you!