Ann Surg Oncol
DOI 10.1245/s10434-014-4145-0

Annals of
SURGICAL ONCOLOGY
OFFICIAL JOURNAL OF THE SOCIETY OF SURGICAL ONCOLOGY

ORIGINAL ARTICLE – ENDOCRINE TUMORS

Consensus Recommendations for the Diagnosis and Management of Pancreatic Neuroendocrine Tumors: Guidelines from a Canadian National Expert Group

Simron Singh, MD, MPH[1], Chris Dey, MD[2], Hagen Kennecke, MD[3], Walter Kocha, MD[4], Jean Maroun, MD[5], Peter Metrakos, MD[6], Tariq Mukhtar, PhD[7], Janice Pasieka, MD[8], Daniel Rayson, MD[9], Corwyn Rowsell, MD[10], Lucas Sideris, MD[11], Ralph Wong, MD[12], and Calvin Law, MD[1]

[1]Department of Medicine, Odette Cancer Centre – Sunnybrook Hospital, University of Toronto, Toronto, ON, Canada; [2]Department of Medical Imaging, Sunnybrook Health Sciences Centre, University of Toronto, Toronto, ON, Canada; [3]BC Cancer Agency, Vancouver, BC, Canada; [4]London Regional Cancer Centre, London, ON, Canada; [5]The Ottawa Hospital, Ottawa, ON, Canada; [6]McGill University Health Centre, Royal Victoria Hospital, Montreal, QC, Canada; [7]Havas Life Toronto, Toronto, ON, Canada; [8]Department Surgery and Oncology, University of Calgary, Calgary, AB, Canada; [9]Queen Elizabeth II Health Sciences Center, Halifax, NS, Canada; [10]Sunnybrook Health Sciences Centre, Toronto, ON, Canada; [11]Hopital Maisonneuve-Rosemont, Montreal, QC, Canada; [12]St. Boniface General Hospital, Winnipeg, MB, Canada

ABSTRACT Pancreatic neuroendocrine tumors (pNETs) are rare heterogeneous tumors that have been steadily increasing in both incidence and prevalence during the past few decades. Pancreatic NETs are categorized as functional (F) or nonfunctional (NF) based on their ability to secrete hormones that elicit clinically relevant symptoms. Specialized diagnostic tests are required for diagnosis. Treatment options are diverse and include surgical resection, intraarterial hepatic therapy, and peptide receptor radionuclide therapy (PRRT). Systemic therapy options include targeted agents as well as chemotherapy when indicated. Diagnosis and management should occur through a collaborative team of health care practitioners well-experienced in managing pNETs. Recent advances in pNET treatment options have led to the development of the Canadian consensus document described in this report. The discussion includes the epidemiology, classification, pathology, clinical presentation and prognosis, imaging and laboratory testing, medical and surgical management, and recommended treatment algorithms for pancreatic neuroendocrine cancers.

© Society of Surgical Oncology 2014

First Received: 29 January 2014

S. Singh, MD, MPH
e-mail: simron.singh@sunnybrook.ca

Published online: 04 November 2014

The panel members in this study included representatives from medical and surgical oncology, pathology, and interventional radiology. The recommendations outlined in this document are based on evidence from the published literature and the collective experience of the authors. Please see Table 1 for all minimal consensus recommendations.

Pancreatic neuroendocrine tumors (pNETs) are a rare heterogeneous group of neoplasms derived from the diffuse neuroendocrine system and arising from pancreatic islet cells.[1,2] The American Joint Committee on Cancer (AJCC) stages pNETs similar to pancreatic adenocarcinomas but differentiates them in terms of cellular origin, incidence, clinical presentation, therapeutic options, and prognosis.[3,4]

Pancreatic NETs can be broadly classified as functional (F-pNETs) or nonfunctional (NF-pNETs) based on their ability to elicit clinical symptoms due to inappropriate neuropeptide hormone secretion.[2] The two most common types of F-pNETs are insulinomas and gastrinomas, with other types including glucagonomas, somatostatinomas, VIPomas, GRHomas, ACTHomas and PTHrp-omas.[5] The management of F-pNET syndromes is specifically addressed elsewhere.[6–8]

EPIDEMIOLOGY

Increasing pNET incidence has been reported across multiple jurisdictions.[2,9] According to the Surveillance, Epidemiology, and End-Results (SEER) 17 registry data, the age-adjusted annual incidence of pNETs in the United States

TABLE 1 Minimal consensus recommendations

Section	Minimal consensus recommendations (level of consensus)
Classification	Both the 2010 WHO and ENETS are acceptable classification systems (1)
	pNETs should be classified according to tumor grade based primarily on Ki67 index and mitotic count and staged according to the AJCC parameters (1)
Pathology	Every pathology report should include the entire CAP checklist plus Ki67 measured at the point of highest proliferation (1)
	Synaptophysin, chromogranin-A, and Ki67 immunohistochemistry are the minimal immunohistochemistry staining
	Diagnosis should be confirmed with core biopsy if possible (1)
	Multiple biopsies may be considered if results are discordant with clinical behavior and where additional information will influence clinical management (2B)
Clinical presentation and prognosis	Prognostic factors to be considered when assessing pNET patients include tumor grade, tumour size, pace of clinical disease progression, disease stage, Ki67 values, and performance status
Imaging and laboratory testing	Appropriate cross-sectional imaging via triphasic CT and/or MRI is recommended for all patients
	EUS is a preferred route for a diagnostic biopsy of a pancreatic mass
	SRS is recommended at the time of diagnostic workup and/or preoperatively
	Measurement of CgA is recommended for all patients
Surgical management	Localized NF-pNETs
	Surveillance of pNETs is reasonable if the tumor is a small solitary lesion ($\leq$ 2 cm) that has demonstrated stability over time (2B)
	Enucleation can be considered in well-selected situations
	Locally advanced NF-pNETs
	Locally advanced pNETs should be considered for surgical resection in the appropriate clinical setting. Surgical oncologic principles as per pancreatic adenocarcinoma should be applied
	Locally advanced disease with vascular invasion does not preclude the option for aggressive resections provided reasonable vascular reconstruction is possible and circumstances favor a positive risk–benefit ratio.
	Non-curative debulking of a locally advanced pNET may be considered in appropriately selected patients
	Metastatic NF-pNETs
	Low-grade, indolent, metastatic tumours should be considered for resection of the primary tumour as well as debulking non-diffuse liver disease
	An experienced multidisciplinary team is required to assess the appropriateness of sequential or simultaneous resections of primary and metastatic tumors.

TABLE 1 continued

Section	Minimal consensus recommendations (level of consensus)
Medical Management	Moderately to Rapidly Progressive Disease
	Clinical and radiologic pace of disease progression is a critical factor in the decision to recommend non-curative medical therapy
	For Grade 1 or 2 disease with unequivocal evidence of significant disease progression, systemic chemotherapy with a temozolamide or a streptozocin-based regimen can be considered
	For G3 patients (especially with a high Ki67 index), platinum-based chemotherapy is the preferred treatment. Possible second line options include temozolamide ± capecitabine
	Adjuvant therapy may only be considered in surgically resected (R0) G3 pancreatic NECs, with treatment similar to small cell carcinoma (chemotherapy) (2B)
	Indolent to moderately progressive disease
	For those cases in which stabilization is the primary goal, targeted therapy is a recommended treatment option
	Both everolimus and sunitinib are considered effective and acceptable therapies (1)
	The choice of agent should be based on patient preference, comorbidities, toxicity profiles, tolerance and availability. Sequential therapy should be considered
	Use of somatostatin analogs is a clinical option if stabilization of the tumor is a primary goal (2B)
	PRRT is an option for those patients with octreotide or MIBG-avid disease; good to excellent performance status; adequate renal, hepatic, and bone marrow function; at least moderate bulk progressive disease; and progressive disease despite consideration and attempts to use other potentially less toxic therapies (2B)

Levels of consensus are defined as 1 (uniform consensus based on high-level evidence that the recommendation is appropriate) 2A (uniform consensus based on lower-level evidence, including clinical experience, that the recommendation is appropriate), 2B (nonuniform consensus, but no major disagreement, based on lower-level evidence, including clinical experience, that the recommendation is appropriate), 3 (major disagreement that the recommendation is appropriate. All recommendations in this statement are category 2A unless otherwise indicated

WHO World Health Organization, *ENETS* European Neuroendocrine Tumor Society, *AJCC* American Joint Committee on Cancer, *CAP* College of American Pathologists, *CT* computed tomography, *MRI* magnetic resonance imaging, *EUS* endoscopic ultrasound, *SRS* somatostatin-receptor scintigraphy, *CgA* chromogranin A, *NF-pNET* nonfunctional pancreatic neuroendocrine tumor, *NEC* neuroendocrine carcinoma, *PRRT* peptide receptor radionuclide therapy, *MIBG* metaiodobenzylguanidine

TABLE 2 Comparison of 2000 and 2010 WHO classifications of pancreatic neuroendocrine tumors (pNETs)

Tumour grade	2000 WHO nomenclature	2010 WHO nomenclature	2010 WHO grading characteristics
Low	Well-differentiated neuroendocrine tumor (grade 1)	NET G1	Mitotic count < 2 per 10 high-power fields (HPF) and/or ≤ 2 % Ki67 index
Intermediate	Well-differentiated neuroendocrine tumor (grade 2)	NET G2	Mitotic count 2–20 per 10 high-power fields (HPF) and/or 3–20 % Ki67 index
High	Neuroendocrine carcinoma (grade 3), large or small cell type	NEC G3	Mitotic count > 20 per 10 high-power fields (HPF) and/or > 20 % Ki67 index

WHO World Health Organization

is 0.32 per 100,000.[10] The peak incidence occurs between the ages of 70 and 79 years, with the rates significantly increasing after the age of 40 years.[11] An estimated 70 to 80 % of pNETs are nonfunctional in nature, and 64 % of patients present with metastatic disease at diagnosis.[2,10,11]

Recent population-based data examining the incidence of all NET subtypes in Ontario showed a rate of 2.46 per 100,000 (95 % confidence interval [CI] 2.13–2.83) in 1994, which rose to 5.86 per 100,000 (95 % CI 5.40–6.35) in 2009. Pancreatic NETs accounted for approximately 10 % of the total cases (0.55 per 100,000 in 2009), with the incidence rate increasing sixfold during this period.[12]

CLASSIFICATION

The 2000 World Health Organization (WHO) classification scheme for NETs (including pNETs) made a clear distinction between well-differentiated NETs and poorly differentiated neuroendocrine carcinomas (NECs) of the small or large cell type.[13] In 2010, WHO updated its classification schemas by adapting a European Neuroendocrine Tumor Society (ENETS) grading system that places considerable emphasis on proliferation and is stage independent. It is based on both mitotic count and Ki67 index, resulting in three categories: NET G1, NET G2, and NEC (large and small cell types) (Table 2).[14] The 2010 WHO guidelines further state that addition of the WHO 2000 staging information is optional and may be included in parentheses for clinicians who wish to classify the lesion further [e.g., NEC G3 (well differentiated) and NEC G3 (poorly differentiated)].[14]

Staging

Tumor-node-metastasis (TNM) staging systems have been developed by both ENETS and AJCC, which provide a relatively consistent approach to pNET staging.[4,15–17] Strosberg et al.[4] validated the AJCC system in a study that analyzed survival outcomes for 425 patients with pNETs (77 % with NF-pNETs). They reported 5-year overall survival rates as a function of AJCC disease stage: 92 % for stage 1, 84 % for stage 2, 81 % for stage 3, and 57 % for stage 4 ($P < 0.001$). Tumor grade also was observed to provide important prognostic information, with 5-year overall survival rates of 75 % for low-grade tumors, 62 % for intermediate-grade tumors, and 7 % for high-grade tumors. It is recommended that clinicians consider this validated AJCC system when staging pNETs.

PATHOLOGY

In an effort to improve the consistency and completeness of pathology reports, the College of American Pathologists (CAP) created standardized templates that assist pathologists in providing clinically useful and relevant information when reporting results of surgical specimen examinations.[18] It is recommended that all pathology reports use the CAP pNET reporting protocol (Table 3).

Immunohistochemistry

Immunohistochemistry staining for chromogranin A, synaptophysin, Ki67, and cytokeratin markers should be performed on all suspected pNET tumors.[19–22] As a nuclear, nonhistone protein, Ki67 is active during mitosis used to assess the ratio of proliferating cells in a given cell population.[23–26] The Ki67 index should be determined by examination of 2,000 tumor cells within areas of greatest immunohistochemical labeling (proliferation).[27] If 2,000 cells are not available, as many cells as possible should be counted, with caveats disclosed during reporting.

Biopsy

Core biopsies should be obtained whenever possible for accurate assessment of the required histologic and immunohistochemical parameters. Given the reliance on Ki67, mitotic rate, and histologic differentiation for management decisions, biopsies of both the primary and metastatic tumors should be considered. A recent study suggested that the Ki67 labeling index may change during the disease course and may differ between primary tumor and metastases (S. Singh, unpublished data).[28] Multiple biopsies may

TABLE 3 Overview of elements required by the CAP protocol for pancreatic neuroendocrine tumors (pNETs)

CAP protocol for pNETs	
Specimen (select all that apply)	
Head of pancreas	Adjacent large vessels
Body of pancreas	Portal vein
Tail of pancreas	Superior mesenteric vein
Duodenum	Other large vessel (specify)
Stomach	Other (specify)
Common bile duct	Not specified
Gallbladder	Cannot be determined
Spleen	
Procedure	
Excisional biopsy (enucleation)	Partial pancreatectomy, pancreatic body
Pancreaticoduodenectomy (Whipple resection), partial pancreatectomy	Partial pancreatectomy, pancreatic tail
Pancreaticoduodenectomy (Whippleresection), total pancreatectomy	Other (specify)
	Not specified
Tumor site (select all that apply)	
Pancreatic head	Other (specify)
Uncinate process	Cannot be determined
Pancreatic body	Not specified
Pancreatic tail	
Tumor size	
Greatest dimension:	
cm (specify size of largest tumor if multiple tumors are present)	
Cannot be determined	
Tumor focality	
Unifocal	Cannot be determined
Multifocal (specify number of tumors)	Not specified
Histologic type and grade	
Not applicable	
Well-differentiated neuroendocrine tumor; GX: Grade cannot be assessed	
Well-differentiated neuroendocrine tumor: G1 (low grade)	
Well-differentiated neuroendocrine tumor: G2 (intermediate grade)	
Other (specify)	
For poorly differentiated (high-grade) neuroendocrine carcinomas, the CAP protocol for carcinoma of the pancreas should be used	
Mitotic rate[a] *(select all that apply)*	
Not applicable	>20 mitoses per 10 HPF
<2 mitoses/10 HPF	Specify mitoses per 10 HPF
Specify mitoses per 10 HPF	Cannot be determined
≥2–20 mitoses/10 HPF	
Specify mitoses per 10 HPF	

TABLE 3 continued

CAP protocol for pNETs	
Microscopic tumor extension (select all that apply)	
Cannot be determined	Tumor invades duodenal wall
No evidence of primary tumor	Tumor invades peripancreatic soft tissues
Tumor is confined to pancreas	Tumor invades other adjacent organs or structures (specify)
Tumor invades ampulla of Vater	
Tumor invades common bile duct	
Margins (select all that apply)	
Cannot be assessed	Distal margin (distal duodenal)
Margins uninvolved by tumor	Uncinate process (retroperitoneal) margin (nonperitonealized surface of the uncinate process)
Distance of tumor from closest margin mm *or* cm	Bile duct margin
Margin(s) involved by tumor	Pancreatic resection margin
Proximal margin (gastric or duodenal)	
Lymph-vascular invasion	
Not identified	Indeterminate
Present	
Perineural invasion	
Not identified	Indeterminate
Present	
Pathologic staging (pTNM)	
TNM descriptors (required only if applicable) (select all that apply)	Regional lymph nodes (pN)
m (multiple primary)	pNX: Cannot be assessed
r (recurrent)	pN0: No regional lymph node metastasis
y (posttreatment)	pN1: Regional lymph node metastasis
	No nodes submitted or found
Primary tumor (pT)	
pTX: Cannot be assessed	Number of lymph nodes examined
pT0: No evidence of primary tumor	Specify:
pT1: Tumor limited to the pancreas, 2 cm or less in greatest dimension	Number cannot be determined (explain)
pT2: Tumor limited to the pancreas, more than 2 cm in greatest dimension	Number of lymph nodes involved
pT3: Tumor extends beyond the pancreas but without involvement of the celiac axis or the superior mesenteric artery	Specify:
pT4: Tumor involves the celiac axis or the superior mesenteric artery	Number cannot be determined (explain)
	Distant metastasis (pM)
	Not applicable
	pM1: Distant metastasis

CAP College of American Pathologists, *HPF* high-power fields, *TNM* tumor-node-metastasis

[a] Determination of Ki67 index is strongly recommended

be considered if results are discordant with clinical behavior and where additional information will influence clinical management.

Clinical Presentation and Prognosis

Pancreatic NETs are commonly discovered incidentally,[5,10,29] with abdominal or back pain, anorexia-cachexia, obstructive jaundice, weight loss, and peptide-specific functional syndromes representing common symptomatic clinical presentations.[2,6,9, 30–32] Tumor stage and grade are independent prognostic factors for pNETs, with 5-year overall survival rates of 57 % for stage 4 disease.[4,11] The SEER data from 1973 to 2004 showed an overall median survival of 42 months among all patients with G1/G2 pNETs.[10] Additional prognostic factors to consider in the assessment of pNET patients include tumor size, pace of clinical disease progression, Ki67 values, and performance status.[33–39]

IMAGING AND LABORATORY TESTING

Imaging

Anatomic Imaging

CT and MRI Appropriate cross-sectional imaging is recommended for all patients. Triphasic computed tomography (CT) is indicated in the initial diagnosis and follow-up evaluation of primary tumors and their distant metastases.[40–42] Magnetic resonance imaging (MRI) technology offers greater sensitivity and specificity in the detection of both pancreatic mass and liver metastases, making it appropriate for surgical planning, particularly for the assessment of smaller lesions.[40,41]

EUS Endoscopic ultrasound (EUS) in conjunction with fine-needle aspiration (FNA) cytology (preferably core biopsy) is a particularly useful diagnostic tool with a reported sensitivity of 81 to 98 % and a specificity of 99 to 100 % for the diagnosis of pancreatic lesions, including pNETs.[43–46] Lesions smaller than 2 cm that clearly demonstrate classical pNET characteristics on MRI or CT scan may not require a biopsy. The biopsy does, however, provide confirmation of a low-grade pNET, allowing for surveillance of this small lesion in selected cases. Any concerns that the lesion may be an adenocarcinoma mandates a biopsy.

Functional Imaging

SRS Somatostatin-receptor scintigraphy (SRS) is a functional imaging method that measures the binding of radiolabeled somatostatin analogs to somatostatin receptors on the surface of NETs. The overall reported sensitivity is 60–90 % for pNETs, depending on the type and size of the tumor, and SRS is recommended at the initial diagnosis for all patients with suspected NETs.[31,47] In addition, SRS also is relevant as a preoperative diagnostic method and as a means of determining eligibility for PRRT. The role of SRS in disease follow-up assessment and surveillance is not clearly established.

Positron emission technology (PET) is not routinely recommended in the diagnosis of pNETs due to low uptake in this indolent disease. The combination of [^{18}F]-fluorodeoxyglucose (FDG) and PET may be useful in the diagnosis of poorly differentiated disease or well-differentiated disease with high proliferation rates or rapid clinical progression.[47–49]

As a positron emitter, ^{68}Ga can be tightly linked to different somatostatin/chelator complexes (DOTATOC, DOTATATE, DOTANOC). Findings show that ^{68}Ga imaging offers higher spatial resolution and image quality than octreoscan.[50,51] Although ^{68}Ga generators are difficult to access for clinical use in Canada, this imaging method is encouraged when available.

LABORATORY WORKUP

Chromogranin A

Chromogranin A (CgA) is a glycoprotein stored and secreted from neuroendocrine cell vesicles.[21] Findings have shown that CgA has considerable utility as an intracellular tumor marker in histopathology studies, with a number of antibodies commercially available for different epitopes.[20] Circulating CgA levels are reportedly elevated in both functional and nonfunctional pNETs, making this protein a recommended diagnostic biomarker.[52] However, CgA elevations should be interpreted with caution because they can occur in other conditions such as ingestion of proton pump inhibitors (PPIs), chronic renal insufficiency, liver dysfunction, other carcinomas, and rheumatoid arthritis.[52] Expression of CgA also can be rapidly decreased upon treatment with SSAs, suggesting that serial measurements may offer greater accuracy and clinically relevancy than a single measurement.[52] The risk of false-positives associated with analyzing circulating CgA levels suggests that tests should be conducted under reasonable clinical suspicion of disease and cross-examined with appropriate imaging and biopsy/immunohistochemical studies (including CgA immunohistochemical testing).[52] Recent studies also have shown that CgA is an important prognostic marker, with higher levels related to inferior prognosis.[53]

Pancreatic Polypeptide

Pancreatic polypeptide is particularly elevated in the presence of NETs originating in the gut mucosa and pancreas.[54] Measurement of circulating levels may offer a diagnostic sensitivity of 57 % in NF-pNETs and 63 % in F-pNETs. Notably, when this marker was analyzed in conjunction with CgA, the diagnostic sensitivity in NF-pNET patients increased to almost 95 %.[55]

Pancreatstatin

Pancreastatin, a peptide fragment of CgA, has recently demonstrated its potential as a diagnostic marker. Raines et al.[56] examined CgA, gastrin, and pancreastatin levels in patients who used PPIs ($n = 30$) compared with levels in a separate control group ($n = 30$). Chronic PPI use resulted in significant increases in CgA and gastrin compared with control subjects. In contrast, the pancreastatin levels in nonusers and chronic PPI users were identical. Rustagi et al.[57] further validated its utility by demonstrating that mean pancreastatin levels were significantly higher in NET patients than in non-NET patients. Interestingly, 29 % of the NET patients with elevated pancreastatin levels had normal CgA levels. The sensitivity and specificity were respectively 64 and 100 % for pancreastatin compared with 43 and 64 % for CgA.

SURGICAL MANAGEMENT

General Principles for Surgical Management of pNETs

Pancreatic NETs should ideally be managed in a multidisciplinary setting. In choosing the appropriate therapy, physicians should adopt an individualized, patient-focused medical management strategy at centers with an interest in the disease, expertise in treating it, and a multidisciplinary approach to patient care.[58]

Surgery with curative intent should be considered in all cases if clinically appropriate and technically feasible. Enucleation for small (≤2 cm) G1 pNETs is an acceptable approach. Larger G1 and G2 pNETs and NECs require the same oncologic principles as those applied to pancreatic adenocarcinomas (Figs. 1, 2, 3).

Localized NF-pNETs

Due to the rise in incidentally discovered small NF-pNETs, a growing body of literature suggests safety in their surveillance.[59, 60] Patients with NF-pNETs 2 cm in size or smaller demonstrated to have low Ki67 and no evidence of invasion or metastatic disease can be considered for surveillance. This would include both anatomic imaging and biochemical monitoring initially every 6 months to ensure stability. Management decisions may be aided by definitive biopsies that can differentiate G1/G2 and G3 tumors. As previously discussed, Ki67 measurements on EUS-FNA samples should be interpreted with care. Once stability is confirmed, less frequent anatomic and functional biochemistry is required (every 12 months).

If surveillance criteria are not met, then removal of localized NF-pNETs (≤2 cm) often is performed via enucleation, resection, or both, with comparable outcomes. Both of these procedures can be performed laparoscopically, but distal pancreatic resection is more frequently performed laparoscopically than enucleation. The surgical approach, either laparoscopic or open, should be based on the same indications, namely, the location of the tumor and its relationship to vital structures, the size of the lesion, and the body habitus of the patient. Pancreas-related complications can occur with either approach.[61–64]

Currently, data do not conclusively indicate that a different treatment algorithm should be considered for pNETs located in the head than for those located in the tail of the pancreas. However, surgical experience with other tumor types suggests that aggressive surgery (e.g., pancreaticoduodenectomy) in the head of the pancreas may result in long-term detrimental effects on patient quality of life. Surgeons are recommended to consider less invasive options if possible.

It is recommended that larger pNETs and G2/NEC lesions be treated with formal oncologic resection procedures such as pancreaticoduodenectomy or distal/central pancreatectomy, with all grossly palpable lymph nodes considered for resection and pathologic analysis. Overall postoperative complication rates of 24–30 % and low in-hospital mortality rates of 1–5 % have been reported.[65, 66] Splenic preservation should be attempted whenever possible providing oncologic principles are not compromised.

Locally Advanced NF-pNETs

Aggressive resections (e.g., multivisceral) of locally advanced G1/G2 pNETs can be technically feasible and have been reported to result in promising disease-free and overall survival rates for appropriately selected candidates.[67–76] It is recommended that surgical oncologic principles as per pancreatic adenocarcinoma be applied, including reasonable vascular reconstitution and management decisions aided by definitive biopsies, which can differentiate G1/G2 and G3 tumors. Noncurative debulking may be considered for appropriately selected patients to aid with other therapies or to provide palliative relief of symptoms (see later).

Venous resections due to tumor invasion of the superior mesenteric/portal vein can be safely performed to maximize the chance of an R0 resection.[73, 77–79] Arterial resections are largely limited to tumor invasion of the

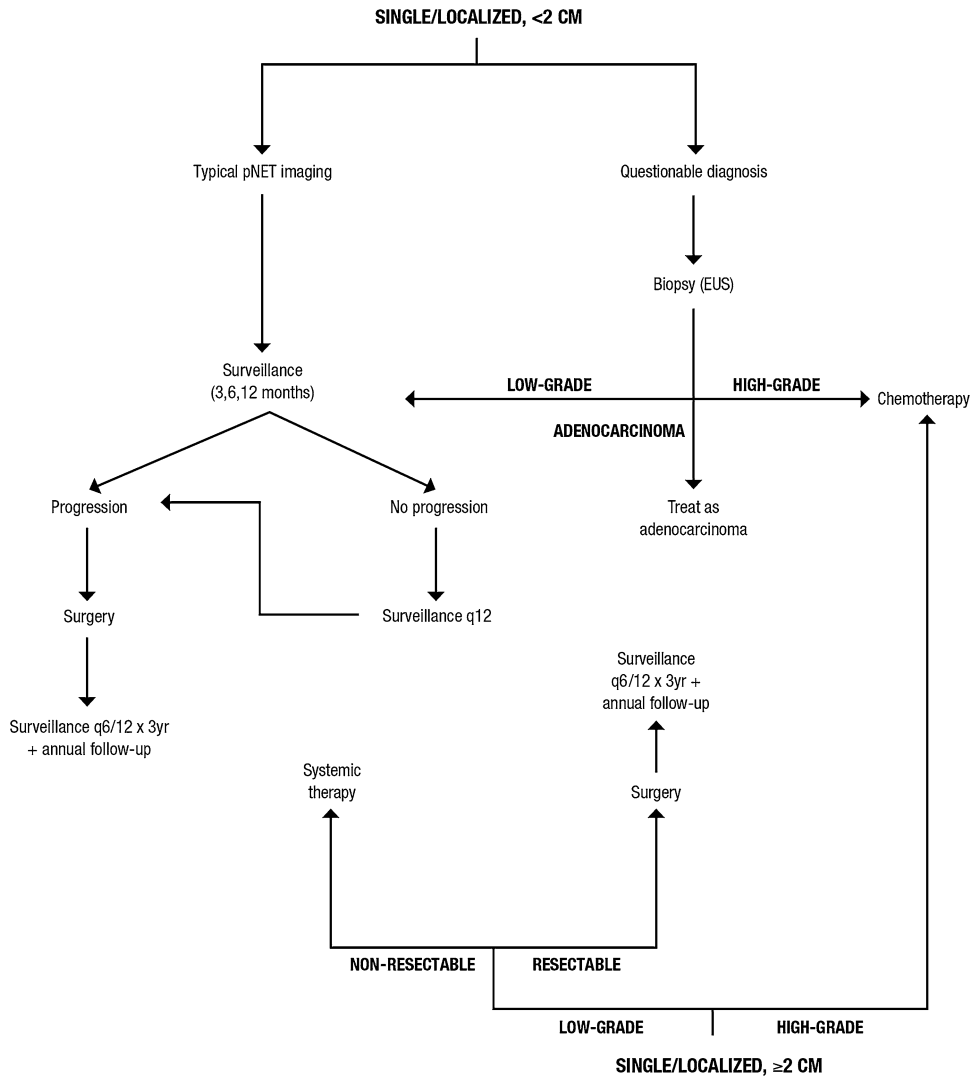

FIG. 1 Treatment algorithm for single localized nonfunctional pancreatic neuroendocrine tumors (NF-pNETs)

hepatic artery at the level of the gastroduodenal artery origin.[78] Patient selection is of critical importance and should be made in a multidisciplinary context.

Metastatic NF-pNETs

Data suggest a limited role for surgical debulking in pNET due to the lack of hormone-based symptoms.[78] However, in certain situations, surgical resection of the primary tumor in the face of metastatic disease may be of benefit.

Palliative pancreaticoduodenectomy may be appropriate for selected G1/G2 patients who have a head-based pNET and an indolent pace of systemic disease progression in order to prevent duodenal obstruction, bleeding, or celiac plexopathy.[78] A recent report suggests that aggressive surgery (resection or ≥90 % debulking) of hepatic metastases in pNET patients may result in significant long-term survival in select cases.[80] Simultaneous resection of the primary tumor and cytoreduction of hepatic metastases may be appropriate for highly select patients as well.[68, 69, 75, 81, 82] An experienced multidisciplinary team should assess the appropriateness of such sequential or simultaneous resections.

A meta-analysis of 1,469 NET patients treated with hepatic resection demonstrated high 5- and 10-year overall survival rates of 70 and 42 %, respectively, with symptomatic improvement demonstrated by 95 % of the patients. Inferior outcomes were reported among the patients with high-grade tumors, extrahepatic disease and incompletely resected tumors, indicating that nonsurgical methods (e.g., preoperative systemic therapy) should be reserved for these patients.[83] Another study comparing outcomes of NET patients treated with intraarterial therapy (IAT) versus hepatic resection found that surgery was associated with superior outcomes only for the patients

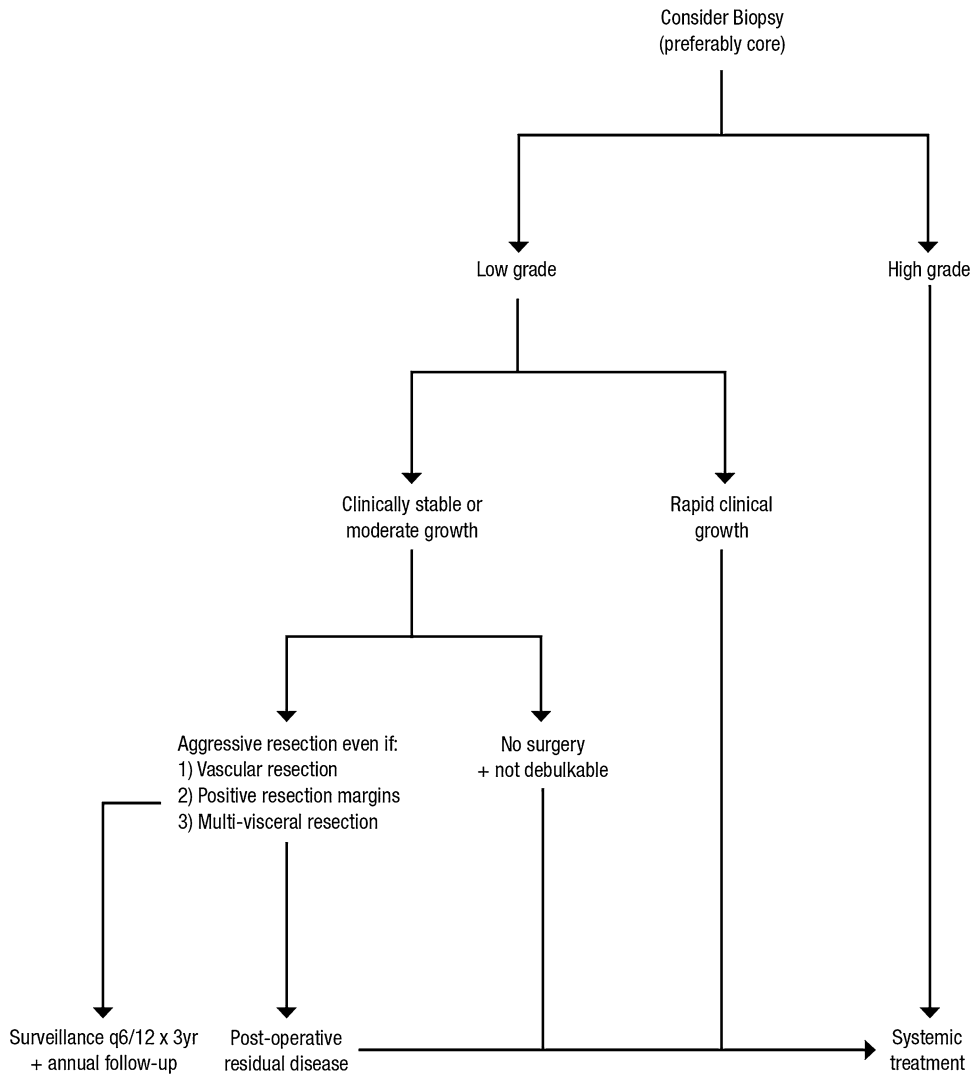

FIG. 2 Treatment algorithm for locally advanced nonfunctional pancreatic neuroendocrine tumors (NF-pNETs)

with bulky tumors who were symptomatic, whereas asymptomatic patients with bulky tumors survived equally long when treated with either surgery or IAT.[84]

Peritoneal Carcinomatosis

Physicians should consider cytoreductive surgery in the exceptional cases of limited visceral disease, small-volume peritoneal disease, and resectable primary and peritoneal carcinomatosis. Hyperthermic intraperitoneal chemotherapy (HIPEC) is not recommended for pNETs due to a lack of high-quality evidence or effective chemotherapeutic agents studied in this setting.[85–87]

Liver Transplantation

Liver transplantation in the treatment of pNETs remains controversial. It is recommended that liver transplantation be considered only in highly select cases, with the patient fulfilling stringent eligibility criteria including the meeting of all standard criteria for liver transplantation, radiographic evidence of disease stability for a minimum of 6 months, low-grade disease without extra hepatic involvement, and age younger than 55 years.[31, 88]

Hepatically Directed Locoregional Therapies

Embolization (bland, chemo-, and radio-) and ablation (radiofrequency, microwave, and cryo-) are additional cytoreductive techniques acceptable for the treatment of locally advanced and metastatic pNETs with hepatic dominant disease.[89, 90] A recent international, multicenter study observed that surgical treatment (resection, ablation, or a combination thereof) of NET liver metastases provided a median 5-year overall survival of 74 %.[84]

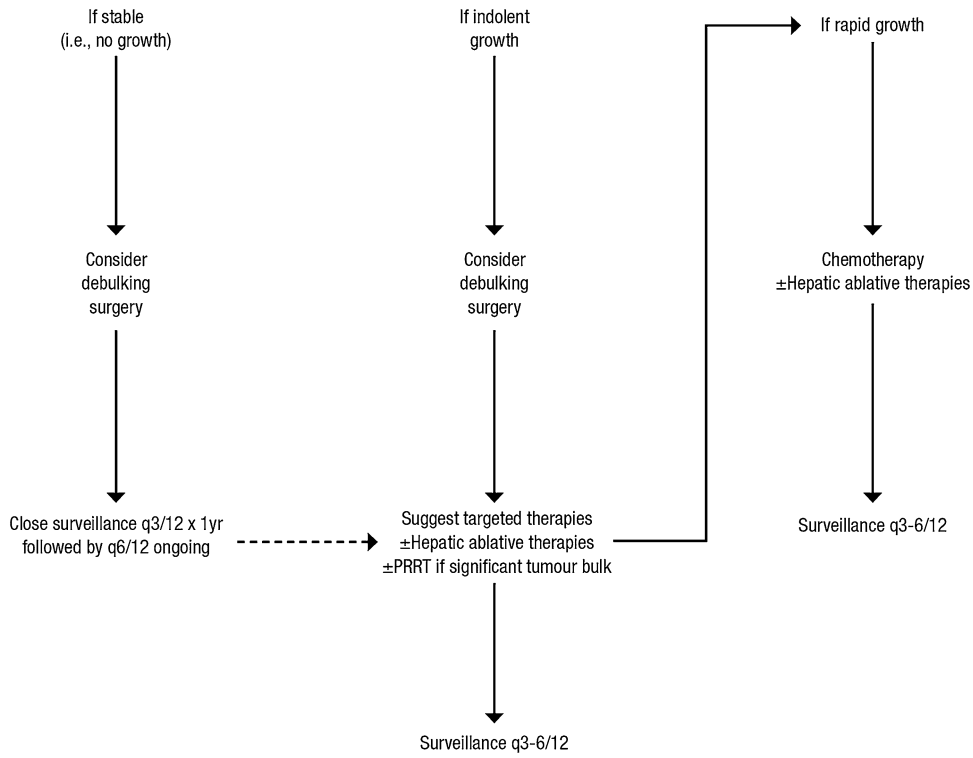

FIG. 3 Treatment algorithm for unresectable or metastatic nonfunctional pancreatic neuroendocrine tumors (NF-pNETs)

MEDICAL MANAGEMENT

Adjuvant Therapy

Currently, no evidence exists to support the use of adjuvant therapy in cases of fully resected pNETs. Consideration should be given for surgically resected (R0) high-grade G3 lesions. Extrapolation from the adjuvant treatment of small cell lung cancer may be considered (adjuvant chemotherapy treatment ± prophylactic cranial irradiation).

Moderately to Rapidly Progressive Disease

Chemotherapy Clinicians have observed that pancreatic NETs are more responsive to systemic chemotherapy than non-pNETs and typically are considered for patients with progressive disease (G3 and rapidly growing G1/G2 tumors). Alkylating agents, including streptozocin and temozolomide, are particularly active in pNETs, whereas platinum combination therapy can be used for G3 and NEC disease.

Streptozocin (STZ) monotherapy was one of the first chemotherapeutic agents approved to demonstrate benefit for patients with metastatic pNETs, albeit with considerable renal and hematologic toxicity.[91] Subsequent studies with STZ + doxorubicin and STZ + fluorouracil demonstrated high response rates of 40–70 % and prolonged progression-free survival (PFS).[92, 93] However, streptozocin currently is not easily obtained on the Canadian market.

In 2011, a single-arm retrospective review investigating the use of oral temozolamide + capecitabine therapy observed a 70 % objective response rate with a median PFS of 18 months and an overall survival of 92 % at 2 years.[94] This combination has not been tested in a randomized, phase 3 clinical trial to date, and it is unknown whether temozolamide monotherapy is as effective. Based on this limited data and with the observation of excellent tolerance, this regimen often is considered as an option for those with progressive or symptomatic disease.

Platinum-based therapy remains the standard first-line option for patients with high-grade or G3 pNETs.[95] Commonly used regimens include cisplatin + etoposide, carboplatin + etoposide, and carboplatin + paclitaxel. A recent study reported that 53 % of patients with metastatic poorly differentiated neuroendocrine carcinoma experienced a major response, with a 3-year survival rate of 24 %, when a carboplatin + etoposide + paclitaxel regimen was used.[96]

The combination of cisplatin + etoposide remains the standard of care for patients who have high-grade or G3 pNETs, with an observed 41.5 % objective response for a duration of 9.2 months (4.5–23.5). Interestingly, recent

data from GI-NEC (G3) patients have shown that patients with a Ki67 of 55 % or more may be more responsive to etoposide and cisplatin therapy than those with a Ki67 lower than 55 %.[97]

Currently, no phase three trials have investigated second-line chemotherapeutic options for high-grade or G3 NETs. However, Welin et al.[98] examined the effects of temozolamide ± capecitabine or capecitabine + bevacizumab in 25 patients with poorly differentiated endocrine carcinoma (10 with pancreas as the primary site). Of these 25 patients, 24 received cisplatin + etoposide as first-line therapy. This regimen demonstrated a 33 % response rate with a median response duration of 19 months. The median progression-free survival for all the patients was 6 months, and the median overall survival time was 22 months.

Indolent to Moderately Progressive Disease

Targeted Therapy For cases with disease stabilization as the primary goal, targeted therapy is a recommended treatment option. Everolimus, an oral inhibitor of the mammalian target of rapamycin (mTOR), and sunitinib, a multi-targeted tyrosine kinase inhibitor represent novel targeted agents for advanced pNETs.

A recent phase 3 clinical trial (RADIANT-3) examining the use of everolimus in 410 patients with advanced-, low-, or intermediate-grade pNETs showed a median PFS of 11 months with everolimus versus 4.6 months with a placebo (HR, 0.35; 95 % CI 0.27–0.45; $P < 0.001$).[99] Adverse events (≥30 % of patients) associated with everolimus were stomatitis, rash, diarrhea, and fatigue.[99] The grade 3 or 4 adverse events occurring in at least 5 % of the patients were anemia, hyperglycemia, and stomatitis.[99]

Another phase 3 trial of 171 patients with advanced well-differentiated pNETs documented a median PFS of 11.4 months for sunitinib compared with 5.5 months for a placebo (HR, 0.42; 95 % CI 0.26–0.66; $P < 0.001$).[100] Adverse events (≥30 % of patients) included diarrhea, nausea, asthenia, vomiting, and fatigue.[100] Grade 3 or 4 adverse events occurring in at least 5 % of the patients with sunitinib were diarrhea, asthenia, fatigue, neutropenia, abdominal pain, hypertension, and palmar-plantar erythrodysesthesia.[100]

Currently, no data have been used to compare everolimus with sunitinib or to assess the sequencing of these agents. The choice of agent should be based on patient preference, comorbidities, toxicity profiles, tolerance, and availability. Substitution of one agent for the other in the context of toxicity or intolerance can be reasonably considered, as can the sequencing of these two agents in the context of disease progression.

Somatostatin Analogs

Somatostatin analogs are indicated for the treatment of secretory NETs. A small randomized, controlled trial (PROMID) demonstrated an improvement in time to tumor progression when octreotide long-acting-release 30-mg IM was compared with placebo for metastatic midgut tumors.[101] Extrapolation of data from the PROMID trial was occasionally considered for pNET tumor stabilization. This application of SSAs was recently validated through CLARINET trial results in which NET patients (including pNETs) randomized to lanreotide showed a significant improvement in PFS compared with placebo.[102]

PRRT

Peptide receptor radionuclide therapy delivers radioisotopes in a targeted fashion and is considered a standard systemic approach among patients with octreotide avid disease.[2, 31] The predominant isotopes used in PRRT are ^{177}Lu and ^{90}Y, with reported response rates ranging from 10 to 30 %.[103–106] In particular, the use of ^{177}Lu-octreotate has been shown to offer a partial response of 36 % in NF-pNET patients 3 months after the last administration.[103] Grade 3 hematologic and renal toxicities are typically reported in 5 to 40 % of patients.[103, 104, 106]

Toxicity of this therapeutic group remains an important consideration because bone marrow toxicity and treatment-related myelodysplastic syndrome may limit future treatment options.[107] As an option, PRRT can be used for patients with metaiodobenzylguanidine (MIBG)/octreotide avid disease; good to excellent performance status; adequate renal, hepatic, and bone marrow function; at least moderate bulk disease; and progressive disease despite consideration or attempted use of other potentially less toxic therapies.[104]

Interferon Alpha

Alpha-IFN monotherapy or alpha-IFN + somatostatin analogs may be offered to improve tumor response and to treat secretory symptoms. However, longer-term use is limited by adverse effects including myalgias, depression, and hematologic toxicities.[2, 108–110] Some practitioners have observed improved tolerance with low-dose regimens (e.g., 3 million units squared three times per week).

CONCLUSION

A multidisciplinary, collaborative, and experienced team of caregivers optimizes the management of patients with pNETs. Ideally, all patients should have the benefit of a

careful clinical review before treatment decisions are finalized. The range of treatment options described in this report should be considered at each clinical decision point because for many patients, different options may be relevant and of considerable benefit at different times in the disease process.

ACKNOWLEDGMENT Funding for development, including consensus meeting costs and honoraria, and editorial support have been provided through an unrestricted educational grant from Novartis Pharmaceuticals Canada. Writing and editing assistance was provided by Havas Life Toronto.

DISCLOSURE There are no conflicts of interest.

REFERENCES

1. Kocha W, Maroun J, Kennecke H, et al. Consensus recommendations for the diagnosis and management of well-differentiated gastroenterohepatic neuroendocrine tumours: a revised statement from a Canadian National Expert Group. *Curr Oncol.* 2010;17:49–64.
2. Metz DC, Jensen RT. Gastrointestinal neuroendocrine tumors: pancreatic endocrine tumors. *Gastroenterology.* 2008;135:1469–92. doi:10.1053/j.gastro.2008.05.047.
3. Ellison TA, Edil BH. The current management of pancreatic neuroendocrine tumors. *Adv Surg* 2012;46:283–96.
4. Strosberg JR, Cheema A, Weber J, Han G, Coppola D, Kvols LK. Prognostic validity of a novel American Joint Committee on Cancer Staging Classification for pancreatic neuroendocrine tumors. *J Clin Oncol.* 2011;29:3044–9. doi:10.1200/JCO.2011.35.1817
5. Massironi S, Sciola V, Peracchi M, Ciafardini C, Spampatti MP, Conte D. Neuroendocrine tumors of the gastro-entero-pancreatic system. *World J Gastroenterol.* 2008;14:5377–84.
6. Jensen RT, Cadiot G, Brandi ML, et al. ENETS Consensus guidelines for the management of patients with digestive neuroendocrine neoplasms: functional pancreatic endocrine tumor syndromes. *Neuroendocrinology.* 2012;95:98–119. doi:10.1159/000335591.
7. Kulke MH, Benson AB III, Bergsland E, et al. Neuroendocrine tumors. *J Natl Compr Canc Netw.* 2012;10:724–64.
8. O'Toole D, Salazar R, Falconi M, et al. Rare functioning pancreatic endocrine tumors. *Neuroendocrinology.* 2006;84:189–95. doi:10.1159/000098011.
9. Falconi M, Plockinger U, Kwekkeboom DJ, et al. Well-differentiated pancreatic nonfunctioning tumors/carcinoma. *Neuroendocrinology.* 2006;84:196–211. doi:10.1159/000098012.
10. Yao JC, Hassan M, Phan A, et al. One hundred years after "carcinoid": epidemiology of and prognostic factors for neuroendocrine tumors in 35,825 cases in the United States. *J Clin Oncol.* 2008;26:3063–3072. doi:10.1200/JCO.2007.15.4377.
11. Halfdanarson TR, Rabe KG, Rubin J, Petersen GM. Pancreatic neuroendocrine tumors (PNETs): incidence, prognosis, and recent trend toward improved survival. *Ann Oncol.* 2008;19:1727–33. doi:10.1093/annonc/mdn351.
12. Cukier M, Law C, Liu N, et al. Epidemiology and survival of neuroendocrine tumors in Ontario: a 15-year population-based study [abstract]. *J Clin Oncol.* 2012;30.
13. Klimstra DS, Modlin IR, Coppola D, Lloyd RV, Suster S. The pathologic classification of neuroendocrine tumors: a review of nomenclature, grading, and staging systems. *Pancreas.* 2010;39:707–12. doi:10.1097/MPA.0b013e3181ec124e.
14. Bosman T, Carneiro F, Hruban R, Theise N. *WHO Classification of Tumours of the Digestive System.* 4th ed. Lyon: IARC Press; 2010. pp. 13–14.
15. Edge SB, Byrd DR, Compton CC, Fritz AG, Greene FL, Trotti A (eds). *AJCC Cancer Staging Manual.* 7th ed. New York: Springer; 2010.
16. Rindi G, Kloppel G, Alhman H, et al. TNM staging of foregut (neuro)endocrine tumors: a consensus proposal including a grading system. *Virchows Arch.* 2006;449:395–401. doi:10.1007/s00428-006-0250-1.
17. Rindi G, Kloppel G, Couvelard A, et al. TNM staging of midgut and hindgut (neuro) endocrine tumors: a consensus proposal including a grading system. *Virchows Arch.* 2007;451:757–62. doi:10.1007/s00428-007-0452-1.
18. Tang L, Berlin J, Branton P, et al. Protocol for the examination of specimens from patients with carcinoma of the endocrine pancreas. College of American Pathologists (CAP); 2013. Pancreas Endocrine 3.2.0.1.
19. Chejfec G, Falkmer S, Grimelius L, et al. Synaptophysin: a new marker for pancreatic neuroendocrine tumors. *Am J Surg Pathol.* 1987;11:241–7.
20. Modlin IM, Gustafsson BI, Moss SF, Pavel M, Tsolakis AV, Kidd M. Chromogranin A: biological function and clinical utility in neuro endocrine tumor disease. *Ann Surg Oncol.* 2010;17:2427–43. doi:10.1245/s10434-010-1006-3.
21. Taupenot L, Harper KL, O'Connor DT. The chromogranin-secretogranin family. *N Engl J Med.* 2003;348:1134–49. doi:10.1056/NEJMra021405.
22. Wiedenmann B, Franke WW, Kuhn C, Moll R, Gould VE. Synaptophysin: a marker protein for neuroendocrine cells and neoplasms. *Proc Natl Acad Sci U S A.* 1986;83:3500–4.
23. Bridger JM, Kill IR, Lichter P. Association of pKi-67 with satellite DNA of the human genome in early G1 cells. *Chromosome Res.* 1998;6:13–24.
24. Bruno S, Darzynkiewicz Z. Cell cycle dependent expression and stability of the nuclear protein detected by Ki-67 antibody in HL-60 cells. *Cell Prolif.* 1992;25:31–40.
25. Endl E, Gerdes J. The Ki-67 protein: fascinating forms and an unknown function. *Exp Cell Res.* 2000;257:231–7. doi:10.1006/excr.2000.4888.
26. Scholzen T, Gerdes J. The Ki-67 protein: from the known and the unknown. *J Cell Physiol.* 2000;182:311–22. doi:10.1002/(SICI)1097-4652(200003)182:3<311::AID-JCP1>3.0.CO;2-9.
27. Klimstra DS, Modlin IR, Adsay NV, et al. Pathology reporting of neuroendocrine tumors: application of the Delphic consensus process to the development of a minimum pathology data set. *Am J Surg Pathol.* 2010;34:300–13. doi:10.1097/PAS.0b013e3181ce1447.
28. Craig J, Cheung M, Law C, Singh S. Ki-67 index variability in neuroendocrine tumors [abstract]. *EMSO.* 2012; abstract 1158P 2012.
29. Zerbi A, Falconi M, Rindi G, et al. Clinicopathological features of pancreatic endocrine tumors: a prospective multicenter study in Italy of 297 sporadic cases. *Am J Gastroenterol.* 2010;105:1421–9. doi:10.1038/ajg.2009.747.
30. Cheslyn-Curtis S, Sitaram V, Williamson RC. Management of nonfunctioning neuroendocrine tumours of the pancreas. *Br J Surg.* 1993;80:625–7.
31. Falconi M, Bartsch DK, Eriksson B, et al. ENETS Consensus guidelines for the management of patients with digestive neuroendocrine neoplasms of the digestive system: well-differentiated pancreatic nonfunctioning tumors. *Neuroendocrinology.* 2012;95:120–34. doi:10.1159/000335587.
32. White TJ, Edney JA, Thompson JS, Karrer FW, Moor BJ. Is there a prognostic difference between functional and nonfunctional islet cell tumors? *Am J Surg.* 1994;168:627–9.

33. Bettini R, Partelli S, Boninsegna L, et al. Tumor size correlates with malignancy in nonfunctioning pancreatic endocrine tumor. *Surgery.* 2011;150:75–82. doi:10.1016/j.surg.2011.02.022.
34. Ekeblad S, Skogseid B, Dunder K, Oberg K, Eriksson B. Prognostic factors and survival in 324 patients with pancreatic endocrine tumor treated at a single institution. *Clin Cancer Res.* 2008;14:7798–803. doi:10.1158/1078-0432.CCR-08-0734.
35. Han JH, Kim MH, Moon SH, et al. Clinical characteristics and malignant predictive factors of pancreatic neuroendocrine tumors. *Korean J Gastroenterol.* 2009;53:98–105.
36. La RS, Sessa F, Capella C, et al. Prognostic criteria in nonfunctioning pancreatic endocrine tumours. *Virchows Arch.* 1996;429:323–33.
37. Panzuto F, Nasoni S, Falconi M, et al. Prognostic factors and survival in endocrine tumor patients: comparison between gastrointestinal and pancreatic localization. *Endocr Relat Cancer.* 2005;12:1083–92. doi:10.1677/erc.1.01017.
38. Panzuto F, Boninsegna L, Fazio N, et al. Metastatic and locally advanced pancreatic endocrine carcinomas: analysis of factors associated with disease progression. *J Clin Oncol.* 2011;29:2372–7. doi:10.1200/JCO.2010.33.0688.
39. Singh S, et al. [Abstract] The role of Ki-67 in the prognosis and management of neuroendocrine (NET) patients in a multidisciplinary cancer center. *Gastrointestinal Cancers Symposium,* 2012; (suppl 4; abstr 184).
40. Noone TC, Hosey J, Firat Z, Semelka RC. Imaging and localization of islet cell tumours of the pancreas on CT and MRI. *Best Pract Res Clin Endocrinol Metab.* 2005;19:195–211. doi:10.1016/j.beem.2004.11.013.
41. Rockall AG, Reznek RH. Imaging of neuroendocrine tumours (CT/MR/US). *Best Pract Res Clin Endocrinol Metab.* 2007;21:43–68. doi:10.1016/j.beem.2007.01.003.
42. Sundin A, Vullierme MP, Kaltsas G, Plockinger U. ENETS Consensus Guidelines for the Standards of Care in Neuroendocrine Tumors: radiological examinations. *Neuroendocrinology.* 2009;90:167–83. doi:10.1159/000184855.
43. Figueiredo FA, Giovannini M, Monges G, et al. Pancreatic endocrine tumors: a large single-center experience. *Pancreas.* 2009;38:936–40. doi:10.1097/MPA.0b013e3181b365db.
44. Jhala NC, Jhala DN, Chhieng DC, Eloubeidi MA, Eltoum IA. Endoscopic ultrasound-guided fine-needle aspiration: a cytopathologist's perspective. *Am J Clin Pathol.* 2003;120:351–67. doi:10.1309/MFRF-J0XY-JLN8-NVDP.
45. Kocjan G. Fine-needle aspiration cytology of the pancreas: a guide to the diagnostic approach. *Coll Antropol.* 2010;34:749–56.
46. Pais SA, Al-Haddad M, Mohamadnejad M, et al. EUS for pancreatic neuroendocrine tumors: a single-center, 11-year experience. *Gastrointest Endosc.* 2010;71:1185–93. doi:10.1016/j.gie.2009.12.006.
47. Teunissen JJ, Kwekkeboom DJ, Valkema R, Krenning EP. Nuclear medicine techniques for the imaging and treatment of neuroendocrine tumours. *Endocr Relat Cancer.* 2011;18(Suppl 1):S27–S51. doi:10.1530/ERC-10-0282.
48. Binderup T, Knigge U, Loft A, Federspiel B, Kjaer A. 18F-fluorodeoxyglucose positron emission tomography predicts survival of patients with neuroendocrine tumors. *Clin Cancer Res.* 2010;16:978–85. doi:10.1158/1078-0432.CCR-09-1759.
49. Vinik AI, Woltering EA, Warner RR, et al. NANETS consensus guidelines for the diagnosis of neuroendocrine tumor. *Pancreas.* 2010;39:713–34. doi:10.1097/MPA.0b013e3181ebaffd.
50. Krausz Y, Freedman N, Rubinstein R, et al. 68Ga-DOTA-NOC PET/CT imaging of neuroendocrine tumors: comparison with (1)(1)(1)In-DTPA-octreotide (OctreoScan(R)). *Mol Imaging Biol.* 2011;13:583–93. doi:10.1007/s11307-010-0374-1.
51. Rufini V, Calcagni ML, Baum RP. Imaging of neuroendocrine tumors. *Semin Nucl Med.* 2006;36:228–47. doi:10.1053/j.semnuclmed.2006.03.007.
52. Singh S, Law C. Chromogranin A: A sensitive biomarker for the detection and posttreatment monitoring of gastroenteropancreatic neuroendocrine tumors. *Expert Rev Gastroenterol Hepatol.* 2012;6:313–34. doi:10.1586/egh.12.15.
53. Yao JC, Pavel M, Phan AT, et al. Chromogranin A and neuron-specific enolase as prognostic markers in patients with advanced pNET treated with everolimus. *J Clin Endocrinol Metab.* 2011;96:3741–9. doi:10.1210/jc.2011-0666.
54. Oberg K. Circulating biomarkers in gastroenteropancreatic neuroendocrine tumours. *Endocr Relat Cancer.* 2011;18(Suppl 1):S17–S25. doi:10.1530/ERC-10-0280.
55. 55.Panzuto F, Severi C, Cannizzaro R, et al. Utility of combined use of plasma levels of chromogranin A and pancreatic polypeptide in the diagnosis of gastrointestinal and pancreatic endocrine tumors. *J Endocrinol Invest.* 2004;27:6–11.
56. Raines D, Chester M, Diebold AE, et al. A prospective evaluation of the effect of chronic proton pump inhibitor use on plasma biomarker levels in humans. *Pancreas.* 2012;41:508–11. doi:10.1097/MPA.0b013e318243a0b6.
57. Rustagi S, Warner RR, Divino CM. Serum pancreastatin: the next predictive neuroendocrine tumor marker. *J Surg Oncol.* 2013;108:126–8. doi:10.1002/jso.23359.
58. Kvols LK, Brendtro KL. The North American Neuroendocrine Tumor Society (NANETS) guidelines: mission, goals, and process. *Pancreas.* 2010;39:705–6. doi:10.1097/MPA.0b013e3181eb7451.
59. Lee LC, Grant CS, Salomao DR, et al. Small, nonfunctioning, asymptomatic pancreatic neuroendocrine tumors (PNETs): role for nonoperative management. *Surgery.* 2012;152:965–74. doi:10.1016/j.surg.2012.08.038.
60. Libutti SK, Inabnet WB III. Force or stratagem? *Surgery.* 2012;152:975–6. doi:10.1016/j.surg.2012.08.061.
61. Crippa S, Bassi C, Salvia R, Falconi M, Butturini G, Pederzoli P. Enucleation of pancreatic neoplasms. *Br J Surg.* 2007;94:1254–9. doi:10.1002/bjs.5833.
62. Hellman P, Goretzki P, Simon D, Dotzenrath C, Roher HD. Therapeutic experience of 65 cases with organic hyperinsulinism. *Langenbecks Arch Surg.* 2000;385:329–36.
63. 63.Park BJ, Alexander HR, Libutti SK, et al. Operative management of islet cell tumors arising in the head of the pancreas. *Surgery.* 1998;124:1056–61.
64. Rothmund M, Angelini L, Brunt LM, et al. Surgery for benign insulinoma: an international review. *World J Surg.* 1990;14:393–8.
65. Muller MW, Friess H, Kleeff J, et al. Is there still a role for total pancreatectomy? *Ann Surg.* 2007;246:966–74. doi:10.1097/SLA.0b013e31815c2ca3.
66. Smith JK, Ng SC, Hill JS, et al. Complications after pancreatectomy for neuroendocrine tumors: a national study. *J Surg Res.* 2010;163:63–8. doi:10.1016/j.jss.2010.04.017.
67. Abu HM, McPhail MJ, Zeidan BA, Jones CE, Johnson CD, Pearce NW. Aggressive multi-visceral pancreatic resections for locally advanced neuroendocrine tumours. is it worth it? *JOP.* 2009;10:276–9.
68. Bonney GK, Gomez D, Rahman SH, et al. Results following surgical resection for malignant pancreatic neuroendocrine tumours: a single institutional experience. *JOP.* 2008;9:19–25.
69. 69.Chen H, Hardacre JM, Uzar A, Cameron JL, Choti MA. Isolated liver metastases from neuroendocrine tumors: does resection prolong survival? *J Am Coll Surg.* 1998;187:88–92.
70. Dousset B, Saint-Marc O, Pitre J, Soubrane O, Houssin D, Chapuis Y. Metastatic endocrine tumors: medical treatment, surgical resection, or liver transplantation. *World J Surg.* 1996;20:908–14.
71. Fendrich V, Langer P, Celik I, et al. An aggressive surgical approach leads to long-term survival in patients with pancreatic endocrine tumors. *Ann Surg.* 2006;244:845–51. doi:10.1097/01.sla.0000246951.21252.60.

72. Hodul PJ, Strosberg JR, Kvols LK. Aggressive surgical resection in the management of pancreatic neuroendocrine tumors: when is it indicated? *Cancer Control.* 2008;15:314–21.
73. Kleine M, Schrem H, Vondran FW, Krech T, Klempnauer J, Bektas H. Extended surgery for advanced pancreatic endocrine tumours. *Br J Surg.* 2012;99:88–94. doi:10.1002/bjs.7681.
74. Norton JA, Kivlen M, Li M, Schneider D, Chuter T, Jensen RT. Morbidity and mortality of aggressive resection in patients with advanced neuroendocrine tumors. *Arch Surg.* 2003;138:859–66. doi:10.1001/archsurg.138.8.859.
75. Sarmiento JM, Que FG, Grant CS, Thompson GB, Farnell MB, Nagorney DM. Concurrent resections of pancreatic islet cell cancers with synchronous hepatic metastases: outcomes of an aggressive approach. *Surgery.* 2002;132:976–82. doi:10.1067/msy.2002.128615.
76. Sasson AR, Hoffman JP, Ross EA, Kagan SA, Pingpank JF, Eisenberg BL. En bloc resection for locally advanced cancer of the pancreas: is it worthwhile? *J Gastrointest Surg.* 2002;6:147–57.
77. Bold RJ, Charnsangavej C, Cleary KR, et al. Major vascular resection as part of pancreaticoduodenectomy for cancer: radiologic, intraoperative, and pathologic analysis. *J Gastrointest Surg.* 1999;3:233–43.
78. Kouvaraki MA, Solorzano CC, Shapiro SE, et al. Surgical treatment of nonfunctioning pancreatic islet cell tumors. *J Surg Oncol.* 2005;89:170–85. doi:10.1002/jso.20178.
79. Tseng JF, Raut CP, Lee JE, et al. Pancreaticoduodenectomy with vascular resection: margin status and survival duration. *J Gastrointest Surg.* 2004;8:935–49. doi:10.1016/j.gassur.2004.09.046.
80. Cusati D, Zhang L, Harmsen WS, et al. Metastatic nonfunctioning pancreatic neuroendocrine carcinoma to liver: surgical treatment and outcomes. *J Am Coll Surg.* 2012;215:117–24. doi:10.1016/j.jamcollsurg.2012.05.002.
81. 81.Chamberlain RS, Canes D, Brown KT, et al. Hepatic neuroendocrine metastases: does intervention alter outcomes? *J Am Coll Surg.* 2000;190:432–45.
82. Hung JS, Chang MC, Lee PH, Tien YW. Is surgery indicated for patients with symptomatic nonfunctioning pancreatic neuroendocrine tumor and unresectable hepatic metastases? *World J Surg.* 2007;31:2392–7. doi:10.1007/s00268-007-9264-3.
83. Saxena A, Chua TC, Perera M, Chu F, Morris DL. Surgical resection of hepatic metastases from neuroendocrine neoplasms: a systematic review. *Surg Oncol.* 2012;21:e131–41. doi:10.1016/j.suronc.2012.05.001.
84. Mayo SC, de Jong MC, Bloomston M, et al. Surgery versus intra-arterial therapy for neuroendocrine liver metastasis: a multicenter international analysis. *Ann Surg Oncol.* 2011;18:3657–65. doi:10.1245/s10434-011-1832-y.
85. Elias D, Sideris L, Liberale G, et al. Surgical treatment of peritoneal carcinomatosis from well-differentiated digestive endocrine carcinomas. *Surgery.* 2005;137:411–6. doi:10.1016/j.surg.2004.11.007.
86. Elias D, David A, Sourrouille I, et al. Neuroendocrine carcinomas: optimal surgery of peritoneal metastases (and associated intraabdominal metastases). *Surgery.* 2014;155:5–12. doi:10.1016/j.surg.2013.05.030.
87. Kianmanesh R, Ruszniewski P, Rindi G, et al. ENETS consensus guidelines for the management of peritoneal carcinomatosis from neuroendocrine tumors. *Neuroendocrinology.* 2010;91:333–40. doi:10.1159/000286700.
88. Steinmuller T, Kianmanesh R, Falconi M, et al. Consensus guidelines for the management of patients with liver metastases from digestive (neuro)endocrine tumors: foregut, midgut, hindgut, and unknown primary. *Neuroendocrinology.* 2008;87:47–62. doi:10.1159/000111037.
89. Kulke MH, Bendell J, Kvols L, Picus J, Pommier R, Yao J. Evolving diagnostic and treatment strategies for pancreatic neuroendocrine tumors. *J Hematol Oncol.* 2011;4:29. doi:10.1186/1756-8722-4-29.
90. Lewis MA, Hobday TJ. Treatment of neuroendocrine tumor liver metastases. *Int J Hepatol.* 2012;973–946. doi:10.1155/2012/973946.
91. Moertel CG, Hanley JA, Johnson LA. Streptozocin alone compared with streptozocin plus fluorouracil in the treatment of advanced islet-cell carcinoma. *N Engl J Med.* 1980;303:1189–94. doi:10.1056/NEJM198011203032101.
92. Kouvaraki MA, Ajani JA, Hoff P, et al. Fluorouracil, doxorubicin, and streptozocin in the treatment of patients with locally advanced and metastatic pancreatic endocrine carcinomas. *J Clin Oncol.* 2004;22:4762–771. doi:10.1200/JCO.2004.04.024.
93. Moertel CG, Lefkopoulo M, Lipsitz S, Hahn RG, Klaassen D. Streptozocin-doxorubicin, streptozocin-fluorouracil or chlorozotocin in the treatment of advanced islet-cell carcinoma. *N Engl J Med.* 1992;326:519–23. doi:10.1056/NEJM199202203260804.
94. Strosberg JR, Fine RL, Choi J, et al. First-line chemotherapy with capecitabine and temozolomide in patients with metastatic pancreatic endocrine carcinomas. *Cancer.* 2011;117:268–75. doi:10.1002/cncr.25425.
95. Mitry E, Baudin E, Ducreux M, et al. Treatment of poorly differentiated neuroendocrine tumours with etoposide and cisplatin. *Br J Cancer.* 1999;81:1351–5. doi:10.1038/sj.bjc.6690325.
96. Hainsworth JD, Spigel DR, Litchy S, Greco FA. Phase II trial of paclitaxel, carboplatin, and etoposide in advanced poorly differentiated neuroendocrine carcinoma: a Minnie Pearl Cancer Research Network Study. *J Clin Oncol.* 2006;24:3548–54. doi:10.1200/JCO.2005.05.0575.
97. Sorbye H, Wekin S, Langer S, et al. Ki-67 Proliferative Index Predicts Response to Chemotherapy and Survival in 252 Patients with High-Grade Gastrointestinal Neuroendocrine Carcinoma (WHO G3) (abstract). North American Neuroendocrine Society Symposium, Abstract C36 2012.
98. Welin S, Sorbye H, Sebjornsen S, Knappskog S, Busch C, Oberg K. Clinical effect of temozolomide-based chemotherapy in poorly differentiated endocrine carcinoma after progression on first-line chemotherapy. *Cancer.* 2011;117:4617–22. doi:10.1002/cncr.26124.
99. Yao JC, Shah MH, Ito T, et al. Everolimus for advanced pancreatic neuroendocrine tumors. *N Engl J Med.* 2011;364:514–23. doi:10.1056/NEJMoa1009290.
100. Raymond E, Dahan L, Raoul JL, et al. Sunitinib malate for the treatment of pancreatic neuroendocrine tumors. *N Engl J Med.* 2011;364:501–13. doi:10.1056/NEJMoa1003825.
101. 101.Ricke J, Klose KJ, Mignon M, Oberg K, Wiedenmann B. Standardisation of imaging in neuroendocrine tumours: results of a European Delphi process. *Eur J Radiol.* 2001;37:8–17.
102. A randomized, double-blind, placebo-controlled study of lanreotide antiproliferative response in patients with gastroenteropancreatic neuroendocrine tumors (CLARINET). The European Cancer Congress; 2013.
103. Kwekkeboom DJ, de Herder WW, Kam BL, et al. Treatment with the radiolabeled somatostatin analog [177 Lu-DOTA 0,Tyr3]octreotate: toxicity, efficacy, and survival. *J Clin Oncol.* 2008;26:2124–30. doi:10.1200/JCO.2007.15.2553.
104. Kwekkeboom DJ, Krenning EP, Lebtahi R, et al. ENETS Consensus Guidelines for the Standards of Care in Neuroendocrine Tumors: peptide receptor radionuclide therapy with radiolabeled somatostatin analogs. *Neuroendocrinology.* 2009;90:220–6. doi:10.1159/000225951.
105. Sowa-Staszczak A, Pach D, Stefanska A, et al. Can treatment using radiolabelled somatostatin analogue increase the survival

rate in patients with nonfunctioning neuroendocrine pancreatic tumours? *Nucl Med Rev Cent East Eur.* 2011;14:73–8.

106. Villard L, Romer A, Marincek N, et al. Cohort study of somatostatin-based radiopeptide therapy with [(90)Y-DOTA]-TOC versus [(90)Y-DOTA]-TOC plus [(177)Lu-DOTA]-TOC in neuroendocrine cancers. *J Clin Oncol.* 2012;30:1100–6. doi:10.1200/JCO.2011.37.2151.
107. Gulenchyn KY, Yao X, Asa SL, Singh S, Law C. Radionuclide therapy in neuroendocrine tumours: a systematic review. *Clin Oncol R Coll Radiol.* 2012;24:294–308. doi:10.1016/j.clon.2011.12.003.
108. 108.Arnold R, Rinke A, Klose KJ, et al. Octreotide versus octreotide plus interferon-alpha in endocrine gastroenteropancreatic tumors: a randomized trial. *Clin Gastroenterol Hepatol.* 2005;3:761–71.
109. Fjallskog ML, Sundin A, Westlin JE, Oberg K, Janson ET, Eriksson B. Treatment of malignant endocrine pancreatic tumors with a combination of alpha-interferon and somatostatin analogs. *Med Oncol.* 2002;19:35–42. doi:10.1385/MO:19:1:35.
110. Modlin IM, Oberg K, Chung DC, et al. Gastroenteropancreatic neuroendocrine tumours. *Lancet Oncol.* 2008;9:61–72. doi:10.1016/S1470-2045(07)70410-2.